

REMITTING SERONEGATIVE SYMMETRICAL SYNOVITIS WITH PITTING EDEMA (RS3PE) – A RARE DISEASE

Arvind Anand¹, Nilesh Kumar¹, Ankur Varshney¹, Sashi Ranjan¹, Jyoti K², Vinay Meena¹

¹ Institute of Medical Sciences, Banaras Hindu University, Varanasi, India

² Ranchi Medical College, Ranchi, Jharkhand, India

Correspondence to: Nilesh Kumar (nilesh19arreno@gmail.com)

DOI: 10.5455/ijmsph.2013.2.234-236 Received Date: 04.12.2012

Accepted Date: 06.12.2012

ABSTRACT

Remitting Seronegative Symmetrical Synovitis with Pitting Edema is a rare clinical entity described as an acute onset polyarthritis with edema affecting geriatric population particularly males. The etiopathogenesis of disease is still elusive but clinical, radiological and immunological characteristics separate it from the more common disease like Rheumatoid arthritis and Polymyalgia rheumatica. Disease has an excellent prognosis with low dose steroids and patients undergo long-term remission even after withdrawal of drugs. We hereby describe a case of 90 year old female presented to us with polyarthritis and pitting edema of hands that we diagnosed as RS3PE.

KEY-WORDS: Seronegative; Synovitis ; Edema; Elderly

Introduction

In 1985, McCarty et al. reported a new clinical entity in 10 patients (8 males & 2 females), who presented with acute onset symmetrical poly-synovitis involving most of their appendicular joints and flexor digitorum tendons associated with pitting edema of the dorsum of both hands and both feet.^[1] In 1990, he along with Hunter and Russel added 13 more case to his original study and established the clinico-radiological pattern of disease.^[2] The definitive diagnostic criteria includes subsets of Seronegative Symmetrical Polyarthritis with dramatic onset of pitting oedema of hands, old age, male predominance, seronegativity for rheumatoid factor, absence of evidences of joint destruction on radiographs, excellent response to low dose steroids with long term remission after withdrawal of drugs. Though the disease itself is benign without any systemic effects, it can also a paraneoplastic manifestation of an occult underlying malignancy like Gastric carcinoma, Non Hodgkin Lymphoma, Chronic Lymphocytic Leukemia and it can also be associated with mycoplasma, pneumonia and amyloidosis.^[3-8]

Case Report

We report a case of 90 years old female with rural background presented with diffuse oedema of dorsum of bilateral hand, severe pain over bilateral wrist joint and bilateral metacarpopharyngeal joint for 45 days, along with multiple tender swellings over the wrist and dorsum of hand for 30 days with negative history of fever, weight loss, fatigability, morning stiffness, backache, neck pain, Rash, eye and orogenital symptoms, mucocutaneous lesion, diarrhoea or any other joint involvement. No significant past, family or personal History was there. Local examination of bilateral Hand showed diffuse oedema of dorsum of hand, which was pitting in nature and tender. There was no redness over the swelling & normal temperature. Apart from that, there were multiple nodular tender swellings present over the wrist & back of hand mobile in transverse direction but not in longitudinal, when the tendons were taut [figure 1]. General and Systemic examination revealed no abnormality. Routine investigation showed no abnormality. Serology was negative for antinuclear antibody and Serum rheumatoid factor, Ultrasound Bilateral Wrist & Hand

Suggestive of tenosynovitis involving extensor and flexor tendons of bilateral wrist.

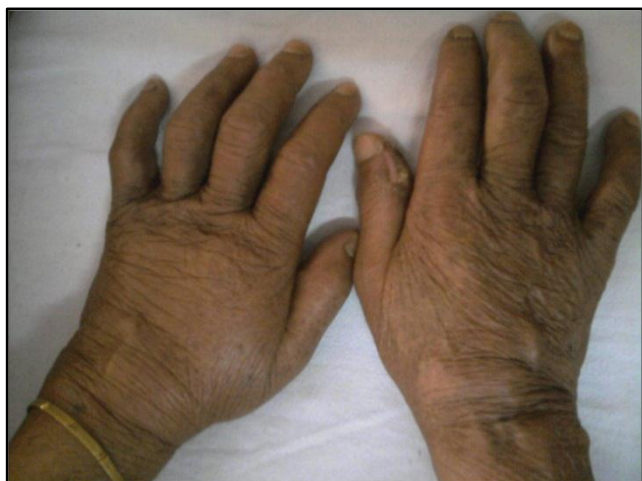

Figure-1: Multiple nodular tender swelling present over the wrist & back of the hand. These swellings are mobile in transverse direction but not in longitudinal when the tendons are taut.

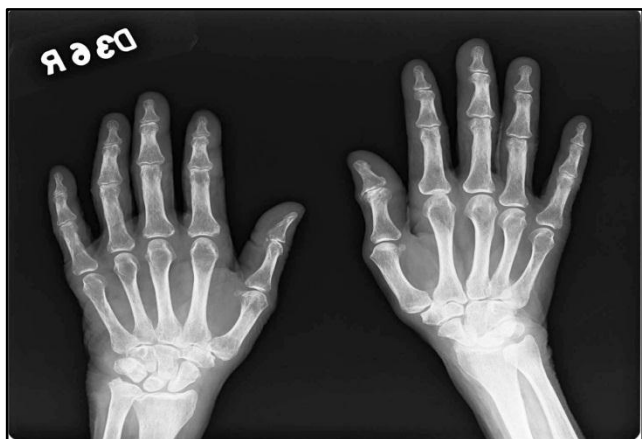

Figure-2: X ray bilateral hand and wrist show no bony erosion

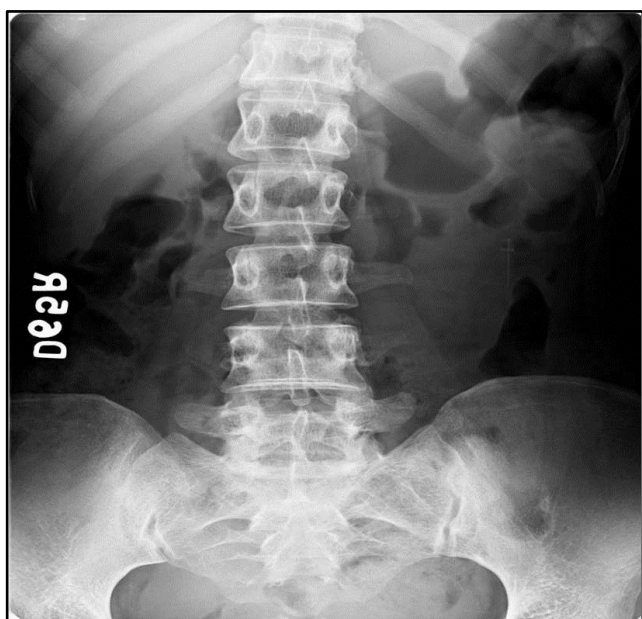


Figure-3: X ray bilateral sacroiliac joint were normal.

X ray bilateral hand and wrist showed no bony erosion and bilateral sacroiliac joint were normal [figure 2 & 3]. On the basis of above findings, we put the diagnosis of Remitting Seronegative Symmetrical Synovitis with pitting edema. we started Low dose steroids (15 mg/day) along with calcium, Patient was dramatically improved after One Week Of Therapy [figure 4]. Patient discharged on low dose steroid as maintenance dose. On follow-up, Patient was in complete remission for the last two months without any symptoms on low dose steroids.

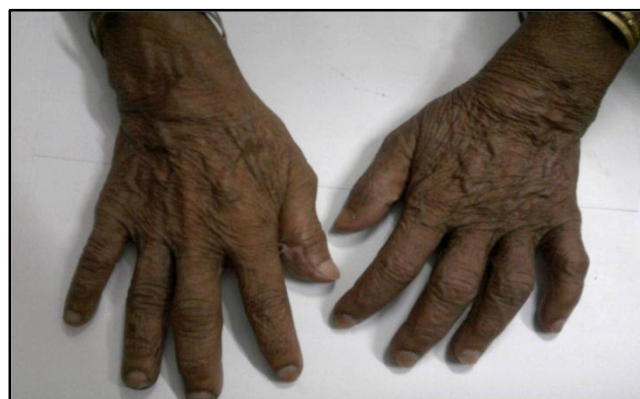

Figure-4: Diffuse edema & swelling completely subsided.

Discussion

Remitting Seronegative Symmetrical Synovitis with Pitting Edema (RS3PE) is a rare syndrome identified by acute onset symmetric polysynovitis, pitting edema of the back of the hands and/or feet and negative serum rheumatoid factor and anti CCP with positive inflammatory markers such as ESR and CRP.^[1] In RS3PE, the word synovitis is used, rather than arthritis because patients presents with symmetrical polysynovitis of joints. The etiology of pitting edema is still unknown, a study by Olivier & colleague noted that on MRI, there is marked extensor tenosynovitis responsible for edema affecting subcutaneous and peritendinous soft tissue.^[9] Later in a study by V Agrawal et al. proved USG colour Doppler to be Gold Standard investigation for diagnosis of tenosynovitis and also proved that extensor tenosynovitis is much more common than flexor tenosynovitis. In the clinical setting, RS3PE is very difficult to diagnose as its clinical presentation is very much similar to other common variants like rheumatoid arthritis (RA) and polymyalgia rheumatic (PMR). The table showing the comparison is given below.

Table-1: Comparison between Rheumatoid Arthritis (RA); Polymyalgia Rheumatic (PMR) and Remitting Seronegative Symmetrical Synovitis with Pitting Edema (RS3P)

Feature	RA	PMR	RS3PE
Onset	Gradual/chronic	Sudden	Acute/Sudden
Sex	F>M	F>M	M>F
Age at onset (decade)	3 rd 5 th	7 th	6 th 9 th
Synovitis	present	Mild	Very severe
Pitting edema	Unusual, if occurs usually asymmetrical, due to joint capsule destruction		+ +
RA factor	+		
HLA association	DR1, DR4	DR3, DR4	HLA B7
Response to steroid	High doses	High dose	Low dose

The disease mechanism (pathophysiology) of RS3PE remains unknown. One study suggested a possible role of vascular endothelial growth factor.^[9] Tenosynovitis of both flexor and extensor tendons at the wrist and the extensor tendons of the feet is the hallmark of RS3PE. Ultrasonography is a reliable and cost effective modality for evaluation of patients with suspected RS3PE, as it characteristically shows tenosynovitis of flexor and extensor tendons.^[10,11] So the conclusion is that we should always keep the possibility of RS3PE in all elderly patients presented with acute onset polysynovitis and pitting edema.

Conclusion

We should always keep the possibility of RS3PE in all elderly patients presented with acute onset polysynovitis and pitting edema. Though rare, the disease has an extremely good prognosis as compare to other common variants like rheumatoid arthritis (RA) and polymyalgia rheumatic (PMR) and patient undergoes remission with only low dose of steroid

References

1. McCarty DJ, O'Duffy JD, Pearson L, Hunter JB. Remitting seronegative symmetrical synovitis with pitting edema - RS3PE syndrome. *JAMA* 1985; 254 (19): 2763-7.
2. Russell EB, Hunter JB, Pearson L, McCarty DJ. Remitting, Seronegative, Symmetrical, Synovitis with pitting edema 13 additional cases. *J Rheumatol* 1990;17(5); 633 -639.
3. Sayarlioglu M. Remmiting Seronegative Symmetrical synovitis with pitting edema and (RS3PE) and malignancy. *Eur J Gen .Med.*2004;1(2):3- 5 .
4. Emiopia A, Bell D. Gastric Carcinoma in association with remitting seronegative symmetrical synovitis with pitting edema. *J Rheumatol* 1999;17;266-7.
5. Goldenbing K, Rozenbaum M .Remitting seronegative symmetrical synovitis with pitting edema (RS3PE) syndrome, secondary to NonHodgkin lymphoma. *Clin Exp. Rheumatol* 1998;16 :767-8.
6. Cobeta Garcia J C, D'Omingo- Morera J A, Martinez B. Remitting seronegative symmetrical synovitis with pitting edema (RS3PE) syndrome, chronic lymphoid leukemia. *Clin Exp Rheumatol* 1999;17:266-7.
7. Mastuda M, Shimajima Y. Remitting seronegative symmetrical synovitis with pitting edema (RS3PE) syndrome/polymyalgia rheumatic after infection with Mycoplasma pneumonia. *Ann Rheum Dis* 2005; 6 4:1797-1798.
8. Finnel JA, Cuesta I A. Remitting seronegative symmetrical synovitis with pitting edema (RS3PE) syndrome: A review of literature and a report of three cases. *J foot Ankle sug* 2000;9:189-96.
9. Cantini F, Salvarani C, Olivieri I, Basozzil et al. Remmiting Seronegative Symmetrical synovitis with pitting edema and (RS3PE)a prospective follow up & magnetic resonance imaging study. *Ann Rheum Dis* 1999; 58:230-6.
10. Agarwal V, Dabra AK, Kaur R, Sachdev A, Singh R. Remitting seronegative symmetrical synovitis with pitting edema (RS3PE) syndrome: ultrasonography as a diagnostic tool. *Clin Rheumatol* 2005; 24 (5): 476-9.
11. Kundu AK. Remitting Seronegative Symmetrical synovitis with pitting edema (RS3PE) syndrome. *J Assoc physician India* 2007; 55 :227- 230.

Cite this article as: Anand, Kumar N, Varshney AN, Ranjan S, Jyoti K, Meena V. Remitting Seronegative Symmetrical Synovitis with Pitting Edema (RS3PE) – A rare disease. *Int J Med Sci Public Health* 2013; 2:456-458.

Source of Support: Nil

Conflict of interest: None declared